

Provocation of obsessive–compulsive symptoms: a quantitative voxel-based meta-analysis of functional neuroimaging studies

Jean-Yves Rotge, MD; Dominique Guehl, MD, PhD; Bixente Dilharreguy, PhD;
Emmanuel Cuny, MD, PhD; Jean Tignol, MD; Bernard Bioulac, MD, PhD;
Michele Allard, MD, PhD; Pierre Burbaud, MD, PhD; Bruno Aouizerate, MD, PhD

Rotge, Guehl, Cuny, Bioulac, Burbaud, Aouizerate — Laboratoire Mouvement Adaptation Cognition, Université Bordeaux 2; Rotge, Tignol, Aouizerate — Service Universitaire de Psychiatrie, Centre Hospitalier Charles Perrens; Guehl, Bioulac, Burbaud — Service de Neurophysiologie Clinique, Centre Hospitalier Universitaire Pellegrin; Dilharreguy, Allard — Laboratoire d'Imagerie Moléculaire et Fonctionnelle, Université Bordeaux 2; Cuny — Service de Neurochirurgie; Allard — Service de Médecine Nucléaire, Centre Hospitalier Universitaire Pellegrin, Bordeaux, France

Objective: Recent functional magnetic resonance imaging (fMRI) and positron emission tomography (PET) studies based on the symptom provocation paradigm have explored neural correlates of the cognitive and emotional processes associated with the emergence of obsessive–compulsive disorder (OCD) symptoms. Although most studies showed the involvement of cortico–subcortical loops originating in the orbitofrontal cortex and the anterior cingulate cortex, an increased activity within numerous other regions of the brain has inconsistently been reported across studies. To provide a quantitative estimation of the cerebral activation patterns related to the performance of the symptom provocation task by OCD patients, we conducted a voxel-based meta-analysis. **Methods:** We searched the PubMed and MEDLINE databases for studies that used fMRI and PET and that were based on the symptom provocation paradigm. We entered data into a paradigm-driven activation likelihood estimation meta-analysis. **Results:** We found significant likelihoods of activation in cortical and subcortical regions of the orbitofrontal and anterior cingulate loops. The left dorsal frontoparietal network, including the dorsolateral prefrontal cortex and precuneus, and the left superior temporal gyrus also demonstrated significant likelihoods of activation. **Conclusion:** Consistent results across functional neuroimaging studies suggest that the orbitofrontal and anterior cingulate cortices are involved in the mediation of obsessive–compulsive symptoms. Based on recent literature, we suggest that activations within the dorsal frontoparietal network might be related to patients' efforts to resist the obsessive processes induced by the provocation task. Further research should elucidate the specific neural correlates of the various cognitive and emotional functions altered in OCD.

Objectif : De récentes études d'imagerie par résonance magnétique fonctionnelle (IRMf) et de tomographie par émission de positrons (TEP) utilisant un paradigme de provocation de symptômes ont exploré les corrélats neuronaux des processus cognitifs et affectifs associés à l'apparition de symptômes du trouble obsessionnel–compulsif (TOC). Même si la plupart des études ont révélé l'importance du rôle de boucles corticales-sous-corticales émanant du cortex orbitofrontal et du cortex cingulaire antérieur, une augmentation de l'activité dans de nombreuses autres régions du cerveau a été rapportée de façon moins systématique. Afin de produire une estimation quantitative des activations cérébrales liées à l'exécution de tâches de provocation de symptômes par des patients atteints de TOC, nous avons procédé à une méta-analyse des données de la littérature. **Méthodes :** Nous avons effectué dans les bases de données PubMed et MEDLINE une recherche d'études ayant utilisé l'IRMf et la TEP et qui reposaient sur le paradigme de provocation des symptômes. Nous avons entré les données dans une méta-analyse d'estimation de la probabilité d'activation. **Résultats :** Nous avons constaté des probabilités importantes d'activation dans les régions corticales et sous-corticales des boucles des cortex orbitofrontale et cingulaire antérieure. L'étude a aussi révélé des probabilités importantes d'activation d'un réseau préfronto–dorso–pariétal gauche, incluant le cortex préfrontal dorsolatéral et le précunéus, ainsi que de le gyrus temporal supérieur gauche. **Conclusion :** Les résultats obtenus indiquent que les cortex orbitofrontal et

Correspondence to: Dr. J.-Y. Rotge, Laboratoire Mouvement Adaptation Cognition, CNRS UMR 5227, Université Bordeaux 2, 146 rue Léo-Saignat, 33076 Bordeaux, France; fax (33) 05 56 90 14 21; jean-yves.rotge@etud.u-bordeaux2.fr

Medical subject headings: obsessive-compulsive disorder; magnetic resonance imaging; positron-emission tomography.

J Psychiatry Neurosci 2008;33(5):405–12.

Submitted Aug. 7, 2007; Revised Nov. 29, 2007; Accepted Jan. 14, 2008

cingulaire antérieure jouent un rôle dans la médiation des symptômes obsessionnels et compulsifs. Compte tenu de publications récentes, nous suggérons que les activations observées dans le réseau préfronto–dorso–pariétal dorsal pourraient être liées aux efforts déployés par les patients pour résister aux processus obsessionnels induits par la provocation de symptômes. D'autres recherches devraient clarifier les corrélats neuronux spécifiquement liés aux diverses fonctions cognitives et affectives affectées dans le TOC.

Introduction

Obsessive–compulsive disorder (OCD) is a chronic and highly disabling condition that affects 2%–3% of the general population. This anxiety disorder is characterized by the presence of obsession in the form of intrusive and distressing thoughts, ideas or images, and by the urge to perform repetitive or ritualistic behaviours known as compulsions.^{1,2} It has been proposed that obsessions are related to the increased evaluation of negative consequences following an action that an individual with OCD wrongly interprets as erroneous or faulty. This persistent high “error signal,” which is considered to be the core of OCD symptomatology, may initiate the pathological doubt that is usually associated with increased anxiety.^{2,5} Compulsions may then occur as behavioural outputs aiming to relieve or to neutralize the anxiety induced by the obsessional process. The relief that may be equated with a form of reward is only transient because performed behaviours do not definitively stop the “error signal,” which leads to a cyclic reproduction of these behaviours.² This phenomenologic view suggests that several cognitive processes such as error detection, together with emotional and motivational functions, may be altered in OCD.^{2,5}

Remarkable advances in functional neuroimaging have recently provided results that showed the participation of several regions of the brain in the cognitive and emotional processes altered in OCD, and their overactivity in patients with the disorder.^{2,6} Indeed, most neuroimaging studies have reported an increased functional activity in the cortico–striato–pallido–thalamo–cortical circuits originating within both the orbitofrontal and the anterior cingulate cortices in OCD patients compared with individuals without the disorder. Furthermore, this basal cortico–subcortical overactivity may be reduced in conjunction with the clinical improvement obtained with efficient treatment.^{2,7} A recent meta-analysis based on the calculation of regional effect sizes across neuroimaging studies that compared functional activity in patients with OCD and healthy individuals found consistent and significant changes in the left orbitofrontal cortex and bilateral caudate nucleus.⁸ However, a meta-analysis using the activation likelihood estimation method may provide further insight, especially regarding the possible roles of other regions of the brain in the pathophysiology of OCD. Voxel-based analysis, which allows a high spatial level of distinction, quantitatively evaluates converging activation foci across functional imaging studies by modelling each activation focus as the centre of a normal probability distribution.⁹ Moreover, recent neuroimaging studies involving patients with OCD have focused on the symptom provocation task, which entails the presentation of obsessional stimuli leading to the produc-

tion of OCD symptoms. Such experimental protocols seem to be more relevant to elicit neural patterns of activations related to the emergence of obsessive–compulsive symptoms than paradigms based on measuring functional activity during a “resting state.” We conducted a paradigm-driven meta-analysis using the activation likelihood estimation method to provide a complete overview of the cerebral networks activated during the symptom provocation task in patients with OCD.

Methods

Literature search and study selection

We searched the PubMed and MEDLINE databases for studies that used functional magnetic resonance imaging (fMRI) and positron emission tomography (PET) to examine brain activity during a symptom provocation task in patients with OCD. Our keywords for the literature search included “obsessive–compulsive disorder” and any of the following terms: “functional magnetic resonance imaging,” “positron emission tomography” and “symptom provocation task.” To obtain additional papers, we manually searched the reference lists of the studies we retrieved.

We included studies in our analysis if they were published in English in a peer-reviewed journal, were restricted to fMRI and PET ($C^{15}O_2$, $H_2^{15}O$ and $^{15}O_2$) scanning techniques that measure highly interrelated biological phenomena,¹⁰ included patients with a primary diagnosis of OCD, were based on a symptom provocation paradigm involving the presentation of obsessional stimuli, described activations at a conventional level of significance and reported the coordinates of activation maxima in a standardized stereotactic space.

One author (J.-Y.R.) identified all articles ($n = 8$)^{11–18} that were published before July 2007 and met our inclusion criteria. Another (B.A.) independently verified and confirmed the study selection.

Data abstraction, coding and correction

We abstracted the coordinates and the volumes of each of 102 activation foci and the corresponding statistical values from conditional contrasts (“symptom provocation condition” minus “neutral condition”). We entered the data into Submit software (BrainMap, University of Texas).¹⁹ Because data on conditional contrasts were unavailable for patients with OCD in the study by Mataix-Cols and colleagues, we considered the between-group contrast (“patients with OCD” minus “individuals without OCD”).¹⁵ To renormalize coordinates spatially into a single stereotactic space, we converted Montréal Neurological Institute coordinates to Talairach coordinates

using Brett transformation.^{20,21} In Talairach space, the *x* coordinate corresponds to the lateromedial distance, the *y* coordinate to the anteroposterior distance, and the *z* coordinate to the superoinferior distance from the anterior commissure. We reported activation extents in cubic millimetres. We calculated voxel size when appropriate using Equation 1.

$$\text{Voxel size} = \frac{\text{Field of view}}{\text{Matrix size}} * \text{Slice thickness}$$

Table 1: Functional neuroimaging studies included in the meta-analysis

Study	Year	Imaging	No. of patients	Treatment	No. of foci
McGuire et al. ¹¹	1994	H ₂ ¹⁵ O PET	4	No	9
Rauch et al. ¹²	1994	C ¹⁵ O ₂ PET	8	Free for 2 wk	5
Breiter et al. ¹³	1996	1.5-T fMRI	8	Yes (n = 8)	26
Rauch et al. ¹⁴	2002	H ₂ ¹⁵ O PET	9	No	11
Mataix-Cols et al. ¹⁵	2004	1.5-T fMRI	33*	Yes (n = 12)	30
Schienle et al. ¹⁶	2005	1.5-T fMRI	10	Yes (n = 5)	13
Nakao et al. ¹⁷	2005	1.5-T fMRI	10	No	7
Shin et al. ¹⁸	2006	H ₂ ¹⁵ O PET	12	Free for 4 wk	1

fMRI = functional magnetic resonance imaging; OCD = obsessive-compulsive disorder; PET = positron emission tomography.

*This study involved 16 patients with OCD and 17 individuals without OCD.

We inserted the statistical values (*t* statistics or *z* scores) corresponding to the maximum or to the mean activation focus in the analysis when available.

Activation likelihood estimation

We completed our activation likelihood estimation using Search&View software (BrainMap, University of Texas).^{19,22,23} We divided the Talairach space into 2 × 2 × 2-mm voxels. Activation foci were modelled by a 3-dimensional normal function with a full width half maximum of 10 mm. We used a permutation test of randomly distributed foci to determine the statistical significance of the resulting activation likelihood estimation values. We performed 5000 permutations with the same full width half maximum value and the same number of foci that we used to compute the activation likelihood estimation values. We then corrected the permutation test for multiple comparisons by using the false discovery rate method.²⁴ We used a statistical threshold of *p* < 0.01 for the generated activation likelihood estimation map, and we did not select a minimum cluster size. We used AFNI software to visualize the activation likelihood estimation map overlaid onto a high-resolution brain template generated by the International Consortium for Brain Mapping.^{25,26}

Table 2: Locations of the main activations reported in the 8 functional neuroimaging studies included in the meta-analysis

Anatomic regions	Study							
	McGuire et al. ¹¹	Rauch et al. ¹²	Breiter et al. ¹³	Rauch et al. ¹⁴	Mataix-Cols et al. ¹⁵	Schienle et al. ¹⁶	Nakao et al. ¹⁷	Shin et al. ¹⁸
Cortical regions								
Frontal cortex								
Orbitofrontal	R (BA 47)	L (BA 11), R (BA 47)	L (BA 11), R (BA 47)	R (BA 11, 47)	L (BA 11), R (BA 11)	L (BA 47), R (BA 47)	L (BA 11)	L (BA 11)
Anterior cingulate		L (BA 32)	L (BA 24), R (BA 24)		L (BA 24), R (BA 32)			
Anterior prefrontal			L (BA 10) R (BA 10)	L (BA 10) R (BA 10)	L (BA 10)		L (BA 10)	
Dorsolateral prefrontal			R (BA 9)	L (BA 9), R (BA 46)	L (BA 9), R (BA 46)	L (BA 9), R (BA 9)		
Ventrolateral prefrontal	R (BA 45)		R (BA 45)		R (BA 44)		L (BA 44)	
Premotor			L (BA 6), R (BA 6)	L (BA 6)	L (BA 6)			
Other frontal regions	L (BA 31)			R (BA 8)	L (BA 4), R (BA 8)			
Other cortical regions								
Insular			L (BA 13), R (BA 13)			L (BA 13), R (BA 13)		
Parietal				L (BA 7)	L (BA 7)	L (BA 39), R (BA 40)	L (BA 19)	
Temporal			L (BA 38), R (BA 38)		L (BA 37)	L (BA 38)	L (BA 19, 21)	
Occipital	L (BA 18)				L (BA 19)			
Subcortical regions								
Striatum	R	R	L, R		R	L		
Globus pallidus	R				R			
Thalamus	R	R			R	L, R		
Hippocampus	L		L, R		R			
Amygdala			L, R					

BA = Brodmann areas; L = left; R = right.

Results

Study selection

We included 8 studies in our meta-analysis (Table 1). Their main results are summarized in Table 2. Of the 8 original studies, 3 studies included patients who received selective serotonin reuptake inhibitor or clomipramin therapy.^{13,15,16} The study by Mataix-Cols and colleagues¹⁵ included patients prescribed additional medications: buspirone ($n = 3$), lithium carbonate ($n = 1$), valproate sodium ($n = 1$) and chlorpromazine ($n = 1$).

Activation likelihood estimation

Results of our activation likelihood estimation based on the provocation of OCD symptoms revealed 19 clusters of significant likelihood for activation. We found significant likelihoods of activation in several cortical regions, including the bilateral orbitofrontal cortex (Brodmann areas [BA] 11, 45, 47), right anterior prefrontal cortex (BA 10), bilateral anterior cingulate cortex (BA 24, 32), left dorsolateral prefrontal cortex (BA 9), left precuneus (BA 7), right premotor cortex (BA 6) and the left superior temporal gyrus (BA 38). In addition, we detected significant likelihoods of activation in the bilateral external globus pallidus, the left hippocampus and in the right uncus. The coordinates, the activation likelihood estimation value and the volume of each cluster are reported in Table 3. Locations demonstrating significant likelihoods of activation are depicted in Figure 1.

Because we used between-group contrasts from Mataix-Cols

and colleagues,¹⁵ we conducted a sensitivity analysis with and without the inclusion of these data to assess the stability of our results. We found no marked differences regarding cerebral regions that demonstrated significant likelihoods of activation with the inclusion of foci reported in this study. However, additional cerebral regions demonstrated significant likelihoods of activation in the analysis without foci from Mataix-Cols and colleagues, including the right insula (BA 13; $x = 44, y = 0, z = 6$), left caudate ($x = -12, y = 12, z = 10$), right posterior cingulate (BA 29; $x = 12, y = -42, z = 12$) and right superior parietal lobule (BA 7; $x = 28, y = -64, z = 46$). The corresponding volume for each of these regions was inferior to 10 mm^3 .

Discussion

A paradigm-driven meta-analysis provides a quantitative estimation of the convergence of activated cerebral regions during the performance of a given paradigm by a given population. Thus a meta-analysis using the activation likelihood estimation method should contribute to elucidating the neural mechanisms underlying pathological processes such as those involved in the production of obsessive-compulsive symptoms. Our study confirmed the importance of well-known cortico-striato-pallido-thalamo-cortical circuits that have been shown to be overactive in OCD. Our study also highlighted the involvement of other cerebral structures in the performance of a symptom provocation task. We found a significant likelihood of activation within frontosubcortical

Table 3: Clusters of significant likelihood for activation based on activation likelihood estimation

Anatomic region*	Coordinates				Volume, mm^3	ALE value† ($\times 10^{-3}$)	Studies reporting foci of activation within the ALE cluster							
	BA	x	y	z			McGuire et al. ¹¹	Rauch et al. ¹²	Breiter et al. ¹³	Rauch et al. ¹⁴	Mataix-Cols et al. ¹⁵	Schienle et al. ¹⁶	Nakao et al. ¹⁷	Shin et al. ¹⁸
L middle frontal gyrus	11	-20	38	-14	632	11.21		√	√		√			
R lateral globus pallidus	—	20	-14	0	536	12.04	√				√			
R medial frontal gyrus	6	4	30	38	496	11.77				√				
R inferior frontal gyrus	47	48	20	-10	432	12.37				√		√		
L middle frontal gyrus	9	-42	14	40	360	11.70					√		√	
L inferior frontal gyrus	47	-24	20	-16	344	9.69			√					√
L superior temporal gyrus‡	38	-44	24	-18	304	12.36						√		
R inferior frontal gyrus	45	44	22	4	248	12.01	√		√					
R uncus	34	16	6	-18	240	11.44		√			√			
R thalamus	—	4	-24	4	168	9.98					√	√		
R middle frontal gyrus	11	32	46	-12	152	9.18			√	√				
L lateral globus pallidus	—	-12	4	0	128	8.9			√			√		
L hippocampus‡	—	-24	-8	-26	112	8.1			√					
L precuneus	7	-12	-66	50	88	8.79				√			√	
R inferior frontal gyrus	47	32	22	-10	64	8.87	√		√					
R middle frontal gyrus	10	36	46	10	40	8.78			√	√				
R anterior cingulate‡	32	12	44	2	32	8.53					√			
R anterior cingulate‡	32	12	42	0	16	9.03					√			
L cingulate gyrus	24	-20	6	44	8	8.17					√	√		

ALE = activation likelihood estimate; BA = Brodmann areas; L = left; R = right.

*Nomenclature of cerebral areas and corresponding Brodmann areas are based on Talairach space.

† $p < 0.01$, corresponding ALE threshold value = 6×10^{-3} .

‡Fewer than 2 studies showed activation within the ALE cluster.

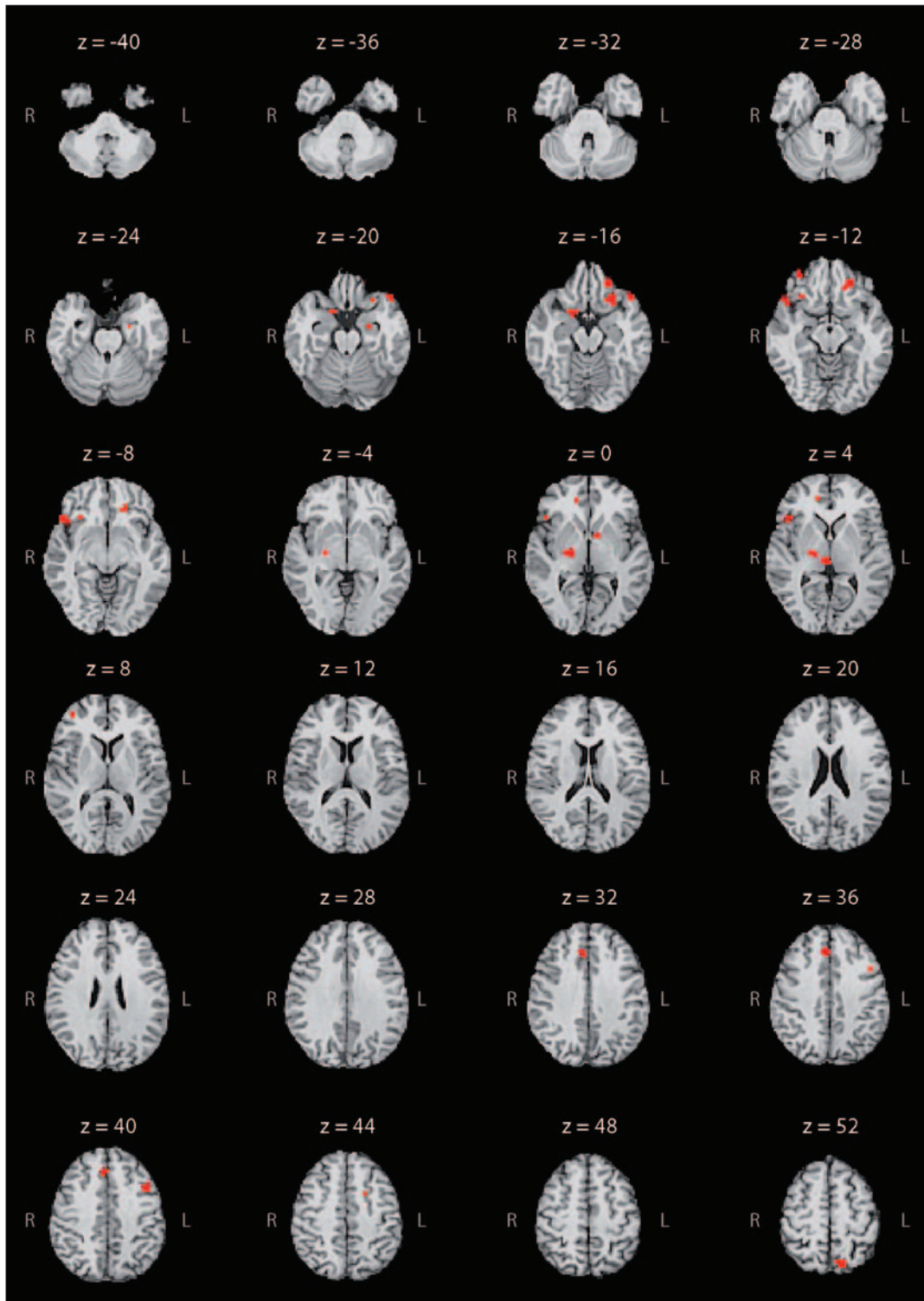


Fig. 1: Meta-analytic activation map based on symptom provocation studies involving patients with obsessive-compulsive disorder. Regions of the brain showing a significant activation likelihood are highlighted in red on axial slices of an individual brain in the Talairach space. They include the bilateral middle and inferior frontal gyri ($z = -16, -12, -8$), bilateral cingulate cortex ($z = 0, 4, 44$), bilateral globus pallidus ($z = -4, 0, 4$), left hippocampus ($z = -24$) and right uncus ($z = -20$). We obtained a unilateral significant threshold in the superior temporal gyrus ($z = -20, -16$) and precuneus ($z = 52$) for the left hemisphere, and in the medial frontal gyrus ($z = 40$) and thalamus ($z = 4$) for the right hemisphere.

loops with high concordance across included studies. We also found significant results in unexpected regions of the brain, such as the temporal and parietal cortices.

The orbitofrontal cortex is commonly distinguished by its medial and lateral parts.²⁷ The medial region extensively connects with the paralimbic–limbic system, including the insular cortex, cingulate gyrus, amygdala and hypothalamus.^{27–30} This area is highly involved in encoding the representation of the value of an expected outcome, which is used to anticipate the positive and negative consequences that are likely to follow a given action.^{28,30} The lateral orbital region is more connected to higher neocortical systems, particularly the dorsolateral prefrontal cortex. The lateral orbital region is thought to play a role in several cognitive processes, such as the selection, comparison and judgment of environmental stimuli, but also in the monitoring of error recognition.^{29,30} These orbitofrontal regions, which are known to be overactive in patients with OCD, might contribute to an increased evaluation of the occurrence of negative consequences following an action.^{2,8} This phenomenon might generate obsessive thoughts that lead to repetitive or ritualistic behaviours intended to prevent negative consequences as a way to relieve anxiety.²

Different versions of the Stroop paradigm have largely contributed to distinguishing a cognitive division (the most dorsal part) and an affective division (the most ventral part) of the anterior cingulate cortex.^{31,32} Several neuroimaging studies have shown that the cognitive division is involved in monitoring conflict and detecting error, whereas the affective division is involved in processing emotion, including the assessment of emotional information and the regulation of emotional responses.³² The cognitive division has extensive connections with the dorsolateral prefrontal and the parietal cortices, as well as with the primary, premotor and supplementary motor areas. The affective division projects more directly to the orbitofrontal cortex, amygdala, nucleus accumbens, hypothalamus and hippocampus, which demonstrated a significant likelihood of activation in our analysis.³³ Overactivity in the cognitive division, as observed in patients with OCD, may be involved in the dysfunctional monitoring of high-conflict situations, placing the patient in a potential position to make an error. Overactivity may also be involved in the increased evaluation among patients with OCD of actions they wrongly interpret as erroneous or faulty.^{2,34,35} Therefore, the cognitive division seems to be involved in the generation of the high “error signal” that is considered to be the core of OCD symptomatology. On the other hand, because of its closed connections with the limbic system, the affective division might mediate the clinical expression of anxiety symptoms associated with the obsessional process.^{2–5}

The orbitofrontal and anterior cingulate cortices have strong connections through the ventral striatum, the pallidum and the medial thalamus. The different levels of these cortico–subcortical loops are thought to be involved in the pathogenesis of OCD. According to our results, the external globus pallidus might play a direct role in the production of obsessive–compulsive symptoms; however, the mechanisms by which it contributes to the emergence of these symptoms remain a matter of debate. It has been reported that OCD

symptoms occur following pallidal lesions; however, micro-injections of a GABAergic antagonist in monkeys induced overactivity in the limbic part of the external globus pallidus, causing the monkeys to repeat particular behaviours.^{36–38} This apparent discrepancy could be related to the precise regions of the external globus pallidus that might be more directly involved in OCD. Our results showed no significant likelihood of activation in the ventral striatum, which is considered to be a crossroads where cognitive, emotional and motivational information abounds via its multiple connections within the frontosubcortical loops. However, there are strong arguments in the literature for considering the striatum, especially the caudate nucleus and nucleus accumbens, to be involved in the mediation of OCD symptoms.

In another study, our research team found that neuronal activity in the caudate nucleus differed according to the presence of OCD symptoms.³⁹ We found an increase in firing rates and neuronal irregularities in 2 of 3 patients with OCD who had surgery for deep brain stimulation. Both patients experienced obsessions during the neuronal recordings.³⁹ Furthermore, several studies have reported the efficacy of deep brain stimulation with the striatal region as a surgical target among patients with OCD that is resistant to treatment.^{40–44} The main reason for the lack of striatal activation in our present meta-analysis could be our choice of a conservative threshold of $\alpha = 0.01$ to minimize type I error. Among the 8 studies included in our analysis, 4 demonstrated activation within the right striatum and 2 demonstrated activation in the left striatum (Table 2). When we applied a less conservative threshold of $\alpha = 0.05$, we identified additional regions, including the caudate nucleus (3 foci, x, y, z : 12, –4, 20; 8, 0, 8; –12, 12, 10). Because the number of foci varied across the studies (owing to heterogeneity of experimental procedures) and because the activation likelihood estimation method attributed equal weight to the findings of each study, it seemed advisable to use a conservative threshold to identify the regions of the brain most commonly involved in the performance of the OCD symptom provocation task.

The significance of the likelihood activation that we observed in the left-sided superior temporal gyrus, precuneus and dorsolateral prefrontal cortex raises the question of their respective roles in the pathophysiology of OCD. The superior temporal gyrus is included in the anterior part of the temporal pole. The temporal pole receives extensive connections from the sensory primary and association cortical areas, and it has dense connections with the affective division of the anterior cingulate cortex, orbitofrontal cortex, amygdala and hypothalamus.⁴⁵ Evidence suggests that the ventral portion of the temporal pole is involved in coupling visceral emotional responses with complex visual stimuli, such as those used in the OCD symptom provocation task.⁴⁶ However, the superior temporal gyrus might be more specifically involved in the pathophysiology of OCD. A morphometric study reported that, compared with individuals without OCD, patients with the disorder had a reduced volume of grey matter in the anterior part of the superior temporal gyrus.⁴⁷ Maihöfner and colleagues⁴⁸ found increased spontaneous magnetoencephalographic activity in the left superior temporal gyrus in OCD

patients compared with individuals without the disorder. Nevertheless, in both studies, neither the volume of the brain nor the increased magnetoencephalographic activity were correlated with the severity of OCD symptoms, as measured with the Yale–Brown Obsessive Compulsive Scale.^{47,48} Consequently, these data suggest that the left superior temporal gyrus is involved in the mediation of the anxiety manifestations commonly experienced by patients with OCD rather than in the genesis of obsessive–compulsive symptoms.

The precuneus corresponds to the medial part of the posterior parietal lobule. Its corticocortical connections include other parietal areas, dorsolateral prefrontal cortex, premotor cortex and both the cognitive and affective divisions of the anterior cingulate cortex. The subcortical projections of the precuneus target the dorsolateral caudate nucleus and putamen.⁴⁹ Together with the dorsolateral prefrontal and anterior cingulate cortices, this parietal region was found to be involved in self-generated thoughts and in the active reallocation of attentional resources.^{49–53} It has been reported that this dorsal frontoparietal network may be related to the active inhibition of the attentional processes associated with a cognitive task and to the voluntary shift of attention across sensory modalities.^{54–57} Thus the likelihood of activation within these cortical areas might be related to patients' efforts to disregard or to turn their attention away from the obsessive and distressing thoughts induced by the symptom provocation task. This possible interpretation is supported by the negative correlations found between the intensity of OCD symptoms induced during the provocation procedure and the activations found within the dorsal frontoparietal network.^{10,15}

Our results suggest that the cerebral activations observed during the performance of a symptom provocation paradigm were related to several cognitive operations or emotions experienced by patients. First, the cortico–subcortical loops originating in the orbitofrontal cortex and in the cognitive division of the anterior cingulate cortex seem to play a major role in the cognitive processes underlying the emergence of OCD symptoms. Second, the affective division of the anterior cingulate cortex and the left superior temporal gyrus may be more directly involved, through their connections with limbic structures, in the clinical manifestations of anxiety that are usually associated with common symptoms of OCD. Third, the left dorsal frontoparietal network may be involved in patients' attempts to turn their attention away from their obsessive thoughts.

Limitations

Our findings have to be interpreted in light of several limitations. First, many patients who participated in the selected studies were prescribed medications to treat OCD, which may have influenced the functional activity in the regions of the brain involved in the mediation of OCD symptoms. Of the 8 included studies, 5 involved unmedicated patients, 2 included both medicated and unmedicated patients, 1 included medicated patients only (Table 1). The small number of foci and studies, and the population heterogeneity concerning medication status, did not make it possible to properly assess the potential effect of medication on likelihoods of activation

during the performance of the OCD symptom provocation task.

Second, the provocation of symptoms belonging to different symptomatic clusters may have caused differential patterns of functional activation.^{58–60} The stimuli presented may, by themselves, induce activations through different cerebral networks.⁶⁰ Unfortunately, the paucity of articles on symptom provocation in patients with OCD did not make it possible to control the wide clinical heterogeneity of the study populations.

Finally, only a very few papers have reported coordinates of activation during obsessive–compulsive symptom provocation in healthy individuals. Thus, to date, no statistical comparison of activation likelihood estimation maps between patients with OCD and healthy individuals can reasonably be performed.

Conclusion

Our study seems to be helpful in highlighting the cortical and subcortical areas involved in performing the OCD symptom provocation task. Our findings confirmed the importance of the cortico–subcortical loops originating in the orbitofrontal and anterior cingulate cortices in the pathogenesis of OCD. They also provide new arguments concerning the putative implication of the temporal cortex in the anxiety manifestations generated by obsessions, especially the hypothetical role of the left dorsal frontoparietal network in resistance to obsessions. To better understand how they interact and lead to the emergence of a given obsessive–compulsive symptom, further research should attempt to determine which regions of the brain are specifically involved in the different cognitive and emotional functions altered in OCD.

Acknowledgements: Dr. Rotge is supported by a grant from the Fondation pour la recherche médicale (Medical Research Foundation). We thank Dr. Ray Cooke for providing advice on English-language wording.

Competing interests: None declared.

Contributors: Dr. Rotge designed the study. Drs. Rotge and Aouizerate acquired the data, which all authors analyzed. Dr. Rotge wrote the article, which Drs. Guehl, Diharreguy, Cuny, Tignol, Bioulac, Allard, Burbaud and Aouizerate reviewed. All authors gave final approval for publication.

References

- Stein DJ. Obsessive-compulsive disorder. *Lancet* 2002;360:397–405.
- Aouizerate B, Guehl D, Cuny E, et al. Pathophysiology of obsessive-compulsive disorder: a necessary link between phenomenology, neuropsychology, imagery and physiology. *Prog Neurobiol* 2004; 72:195–221.
- Schwartz JM. Neuroanatomical aspects of cognitive-behavioural therapy response in obsessive-compulsive disorder. An evolving perspective on brain and behaviour. *Br J Psychiatry Suppl* 1998;35:38–44.
- Schwartz JM. A role of volition and attention in the generation of new brain circuitry. Toward a neurobiology of mental force. *J Consciousness Stud* 1999;6:115–42.
- Pitman RK. A cybernetic model of obsessive-compulsive psychopathology. *Compr Psychiatry* 1987;28:334–43.
- Aouizerate B, Guehl D, Cuny E, et al. Updated overview of the putative role of the serotonergic system in obsessive-compulsive disorder. *Neuropsychiatr Dis Treat* 2005;1:231–43.
- Baxter LR, Schwartz JM, Bergman KS, et al. Caudate glucose metabolic rate changes with both drug and behavior therapy for obsessive-

- compulsive disorder. *Arch Gen Psychiatry* 1992;49:681-9.
8. Whiteside SP, Port JD, Abramowitz JS. A meta-analysis of functional neuroimaging in obsessive-compulsive disorder. *Psychiatry Res* 2004;132:69-79.
 9. Laird AR, McMillan KM, Lancaster JL, et al. A comparison of label-based review and ALE meta-analysis in the Stroop task. *Hum Brain Mapp* 2005;25:6-21.
 10. Ito H, Ibaraki M, Kanno I, et al. Changes in cerebral blood flow and cerebral oxygen metabolism during neural activation measured by positron emission tomography: comparison with blood oxygenation level-dependent contrast measured by functional magnetic resonance imaging. *J Cereb Blood Flow Metab* 2005;25:371-7.
 11. McGuire PK, Bench CJ, Frith CD, et al. Functional anatomy of obsessive-compulsive phenomena. *Br J Psychiatry* 1994;164:459-68.
 12. Rauch SL, Jenike MA, Alpert NM, et al. Regional cerebral blood flow measured during symptom provocation in obsessive-compulsive disorder using oxygen 15-labeled carbon dioxide and positron emission tomography. *Arch Gen Psychiatry* 1994;51:62-70.
 13. Breiter HC, Rauch SL, Kwong KK, et al. Functional magnetic resonance imaging of symptom provocation in obsessive-compulsive disorder. *Arch Gen Psychiatry* 1996;53:595-606.
 14. Rauch SL, Shin LM, Dougherty DD, et al. Predictors of fluvoxamine response in contamination-related obsessive compulsive disorder: a PET symptom provocation study. *Neuropsychopharmacology* 2002;27:782-91.
 15. Mataix-Cols D, Wooderson S, Lawrence N, et al. Distinct neural correlates of washing, checking, and hoarding symptom dimensions in obsessive-compulsive disorder. *Arch Gen Psychiatry* 2004;61:564-76.
 16. Schienle A, Schäfer A, Stark R, et al. Neural responses of OCD patients towards disorder-relevant, generally disgust-inducing and fear-inducing pictures. *Int J Psychophysiol* 2005;57:69-77.
 17. Nakao T, Nakagawa A, Yoshiura T, et al. Brain activation of patients with obsessive-compulsive disorder during neuropsychological and symptom provocation tasks before and after symptom improvement: a functional magnetic resonance imaging study. *Biol Psychiatry* 2005;57:901-10.
 18. Shin YW, Kwon JS, Kang DH, et al. Altered neural circuit for working memory before and after symptom provocation in patients with obsessive-compulsive disorder. *Acta Psychiatr Scand* 2006;113:420-9.
 19. Laird AR, Lancaster JL, Fox PT. BrainMap: the social evolution of a functional neuroimaging database. *Neuroinformatics* 2005;3:65-78.
 20. Talairach J, Tournoux P. *Co-planar stereotactic atlas of the human brain*. New York: Thieme Medical Publishers; 1988.
 21. Brett M. *The MNI brain and the Talairach atlas*. Cambridge, England: MRC Cognition and Brain Sciences Unit; 1999. Available: www.mrc-cbu.cam.ac.uk/Imaging/mnispace.html (accessed 2008 June 25).
 22. Turkeltaub PE, Eden GF, Jones KM, et al. Meta-analysis of the functional neuroanatomy of single-word reading: method and validation. *Neuroimage* 2002;16:765-80.
 23. Laird AR, Fox M, Price CJ, et al. ALE meta-analysis: controlling the false discovery rate and performing statistical contrasts. *Hum Brain Mapp* 2005;25:155-64.
 24. Genovese CR, Lazar NA, Nichols T. Thresholding of statistical maps in functional neuroimaging using the false discovery rate. *Neuroimage* 2002;15:870-8.
 25. Cox RW. AFNI: software for analysis and visualization of functional magnetic resonance neuroimages. *Comput Biomed Res* 1996;29:162-73.
 26. Kochunov P, Lancaster J, Thompson P, et al. An optimized individual target brain in the Talairach coordinate system. *Neuroimage* 2002;17:922-7.
 27. Kringelbach ML, Rolls ET. The functional neuroanatomy of the human orbitofrontal cortex: evidence from neuroimaging and neurophysiology. *Prog Neurobiol* 2004;72:341-72.
 28. Fellows LK. Advances in understanding ventromedial prefrontal function: the accountant joins the executive. *Neurology* 2007;68:991-5.
 29. Krawczyk DC. Contributions of the prefrontal cortex to the neural basis of human decision making. *Neurosci Biobehav Rev* 2002;26:631-64.
 30. Wallis JD. Orbitofrontal cortex and its contribution to decision-making. *Annu Rev Neurosci* 2007;30:31-56.
 31. Whalen PJ, Bush G, McNally RJ, et al. The emotional counting Stroop paradigm: a functional magnetic resonance imaging probe of the anterior cingulate affective division. *Biol Psychiatry* 1998;44:1219-28.
 32. Bush G, Luu P, Posner MI. Cognitive and emotional influences in anterior cingulate cortex. *Trends Cogn Sci* 2000;4:215-22.
 33. Devinsky O, Morrell MJ, Vogt BA. Contributions of anterior cingulate cortex to behaviour. *Brain* 1995;118:279-306.
 34. Holroyd CB, Nieuwenhuis S, Yeung N, et al. Dorsal anterior cingulate cortex shows fMRI response to internal and external error signals. *Nat Neurosci* 2004;7:497-8.
 35. Fitzgerald KD, Welsh RC, Gehring WJ, et al. Error-related hyperactivity of the anterior cingulate cortex in obsessive-compulsive disorder. *Biol Psychiatry* 2005;57:287-94.
 36. Rodrigo Escalona P, Adair JC, Roberts BB, et al. Obsessive-compulsive disorder following bilateral globus pallidus infarction. *Biol Psychiatry* 1997;42:410-2.
 37. Demirkol A, Erdem H, Inan L, et al. Bilateral globus pallidus lesions in a patient with Tourette syndrome and related disorders. *Biol Psychiatry* 1999;46:863-7.
 38. Grabli D, McCairn D, Hirsch EC, et al. Behavioural disorders induced by external globus pallidus dysfunction in primates: I. Behavioural study. *Brain* 2004;127:2039-54.
 39. Guehl D, Benazzou A, Aouizerate B, et al. Neuronal correlates of obsessions in the caudate nucleus. *Biol Psychiatry* 2008;63:557-62.
 40. Aouizerate B, Rotge JY, Martin-Guehl C, et al. A systematic review of psychosurgical treatments for obsessive-compulsive disorder: Does deep brain stimulation represent the future trend in psychosurgery? *Clin Neuropsychiatry* 2006;3:391-403.
 41. Aouizerate B, Cuny E, Martin-Guehl C, et al. Deep brain stimulation of the ventral caudate nucleus in the treatment of obsessive-compulsive disorder and major depression. *J Neurosurg* 2004;101:682-6.
 42. Aouizerate B, Martin-Guehl C, Cuny E, et al. Deep brain stimulation for OCD and major depression. *Am J Psychiatry* 2005;162:2192.
 43. Sturm V, Lenartz D, Koulousakis A, et al. The nucleus accumbens: a target for deep brain stimulation in obsessive-compulsive and anxiety-disorders. *J Chem Neuroanat* 2003;26:293-9.
 44. Greenberg BD, Malone DA, Friehs GM, et al. Three-year outcomes in deep brain stimulation for highly resistant obsessive-compulsive disorder. *Neuropsychopharmacology* 2006;31:2384-93.
 45. Barbas H, Medalla M, Alade O, et al. Relationship of prefrontal connections to inhibitory systems in superior temporal areas in the rhesus monkey. *Cereb Cortex* 2005;15:1356-70.
 46. Olson IR, Plotzker A, Ezzyat Y. The enigmatic temporal pole: a review of findings on social and emotional processing. *Brain* 2007;130:1718-31.
 47. Choi JS, Kim HS, Yoo SY, et al. Morphometric alterations of anterior superior temporal cortex in obsessive-compulsive disorder. *Depress Anxiety* 2006;23:290-6.
 48. Maihöfner C, Sperling W, Kaltenhäuser M, et al. Spontaneous magnetoencephalographic activity in patients with obsessive-compulsive disorder. *Brain Res* 2007;1129:200-5.
 49. Cavanna AE, Trimble MR. The precuneus: a review of its functional anatomy and behavioural correlates. *Brain* 2006;129:564-83.
 50. McGuire PK, Palesu E, Frackowiak RS, et al. Brain activity during stimulus independent thought. *Neuroreport* 1996;7:2095-9.
 51. Den Ouden HEM, Frith U, Frith C, et al. Thinking about intentions. *Neuroimage* 2005;28:787-96.
 52. Mazoyer P, Wicker B, Fonlupt P. A neural network elicited by parametric manipulation of the attention load. *Neuroreport* 2002;13:2331-4.
 53. Fugelsang JA, Dunbar KN. Brain-based mechanisms underlying complex causal thinking. *Neuropsychologia* 2005;43:1204-13.
 54. Corbetta M, Shulman GL. Control of goal-directed and stimulus-driven attention in the brain. *Nat Rev Neurosci* 2002;3:201-15.
 55. McKiernan KA, D'Angelo BR, Kaufman JN, et al. Interrupting the "stream of consciousness": an fMRI investigation. *Neuroimage* 2006;29:1185-91.
 56. Yantis S, Schwarzbach J, Serences JT, et al. Transient neural activity in human parietal cortex during spatial attention shifts. *Nat Neurosci* 2002;5:995-1002.
 57. Shomstein S, Yantis S. Control of attention shifts between vision and audition in human cortex. *J Neurosci* 2004;24:10702-6.
 58. Baer L. Factor analysis of symptom subtypes of obsessive compulsive disorder and their relation to personality and tic disorders. *J Clin Psychiatry* 1994;55(suppl):18-23.
 59. Leckman JF, Grice DE, Boardman J, et al. Symptoms of obsessive-compulsive disorder. *Am J Psychiatry* 1997;154:911-7.
 60. Mataix-Cols D, Cullen S, Lange K, et al. Neural correlates of anxiety associated with obsessive-compulsive symptom dimensions in normal volunteers. *Biol Psychiatry* 2003;53:482-93.